

A new *KRT16* mutation associated with a phenotype of pachyonychia congenita

Francesc Paris¹, Cristina Hurtado¹, Antoni Azón², Leyre Aguado³ and José L. Vizmanos¹

¹Department of Biochemistry & Genetics, School of Sciences, University of Navarra, Pamplona, Spain; ²Department of Dermatology, University Hospital Sant Joan, Universitat Rovira i Virgili, Reus, Spain; ³Department of Dermatology, Clínica Universidad de Navarra, Pamplona, Spain
Correspondence: José L. Vizmanos, PhD, Department of Biochemistry & Genetics, School of Sciences, University of Navarra, Research Building. C/ Irunlarrea 1, E-31008 Pamplona, Spain, Tel.: +0034-948425600, Fax: +0034-948425740, e-mail: jlvizmanos@unav.es

Abstract: Pachyonychia congenita is a rare, autosomal dominant genetic disease characterized by painful palmoplantar keratoderma and hypertrophic nail dystrophy. This disorder is caused by mutations in any one of five cytoskeletal keratin proteins, K6a, K6b, K6c, K16 and K17. Here, we describe a new p.Leu421Pro (c.1262T>C) mutation in the highly conserved helix termination motif of K16 in a large Spanish family. Bioinformatic analyses as

well as previous descriptions in the literature of homologous mutations in other keratin-coding genes show that this mutation is probably causative of the disease.

Key words: keratin – *KRT16* – PC

Accepted for publication 4 October 2013

Background

Pachyonychia congenita (PC; OMIM #167200 and #167210) is a rare, autosomal dominant genetic disorder characterized by painful palmoplantar keratoderma and hypertrophic nail dystrophy and sometimes oral leukokeratosis, follicular keratosis and epidermal cysts (1). PC is caused by mutations in *KRT6A*, *KRT6B*, *KRT6C*, *KRT16* and *KRT17* that encode cytoskeletal keratin proteins (2,3). These proteins are predominantly expressed in basal/suprabasal layers of palmoplantar skin, as well as in epidermal appendages and oral mucosa, forming a dense cytoplasmic network. Mutations can disrupt this cytoskeletal system leading to cellular fragility.

Historically, PC has been split into two subtypes (PC-1 or Jassasohn–Lewandowski subtype; and PC-2 or the Jackson–Lawler subtype) based on minor differences in phenotype. However, data from the International PC Research Registry (IPCR, www.pachyonychia.org) show an important phenotypic overlap in which the affected gene seems to be important. In patients with *KRT16* mutations, dystrophic nails and persistent palmoplantar keratoderma (typically non-epidermolytic) are the most prominent symptoms; however, mutations in *KRT16* can also be associated with painful palmoplantar keratoderma but with little or no nail involvement (2–8). For this reason, a new classification has been proposed (e.g. PC-16 for patients with *KRT16* mutations) (1,9).

Questions addressed

Here, we describe a new mutation in *KRT16* in a large family. This mutation affects an ultraconserved residue in the 2B subdomain of K16. Other mutations affecting homologous positions have been described in other keratin genes. The conservation of this residue plus bioinformatic analyses suggests that this change is pathogenic. This report will be useful to delineate possible genotype-phenotype associations in these diseases.

Experimental design

Individuals from a large family from Spain were referred to our department to analyse mutations on keratin genes. Affected members exhibited focal plantar keratoderma (Fig. 1, a & b) that had appeared when they started to walk (about 2 years old). Slight focal palmar keratoderma was present in individuals who regularly

play tennis. Some affected members also have hypertrophic nails that had appeared after local trauma (Fig. 1 c & d). No one showed epidermal cysts or oral lesions.

A skin biopsy was collected from the plantar lesion of one affected member (#035, Fig. 2a) and showed non-epidermolytic keratoderma (Fig. 1, e–g). Pedigree analysis (Fig. 2a) showed that phenotype was transmitted as an autosomal dominant form. According to OMIM, focal non-epidermolytic plantar keratoderma (FNEPPK, #613000) is caused by mutations in *KRT16*.

The mutation was identified by direct sequencing of PCR products from exons 1–3 and 4–8 in every sample from the pedigree (10). In addition, we performed a complete *in silico* and comparative analysis to predict effects of this change on protein function (supplementary information).

Results

Sequence analysis showed a heterozygous missense mutation in all affected individuals from the pedigree which was not observed in the individuals without disease. This mutation was a c.1262T>C change (according to NM_005557.3) in exon 7 that codes for a Leu to Pro change in residue 421 of the protein (p.Leu421Pro according to NP_005548.2) (Fig. 2b) affecting helix termination motif (HTM) of the 2B subdomain of K16 (Fig. 2c). Data from *Human Intermediate Filament Database* (www.interfil.org) updated on November 2012 showed that two of the 20 different mutations reported in this gene affect 2B region and only one [p.(Ala415_Glu422del) + (Glu424Gln)] is located in HTM (7). This sequence change does not appear as polymorphism in public databases (dbSNP and 1000 genomes).

Comparative analyses of amino acid sequence of K16 2B domain show a high degree of conservation between mammals (Figure S1). Although this conservation is lower if comparing human type I & II keratins, Leu is also present in all of them in homologous positions to 421 which might suggest an important functional role. HTM domain is the most conserved among keratins. Experimental analysis examining the molecular effect of a mutation is laborious and requires a good model. However, some information about the effects of non-synonymous changes can be

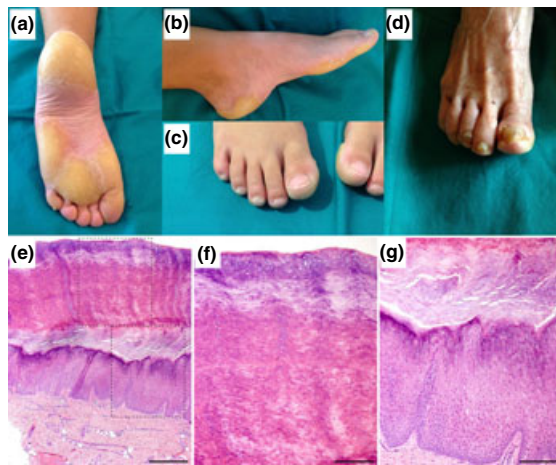

Figure 1. (a) Focal plantar keratoderma in a 13-year-old male patient (#108). (b) Focal plantar keratoderma in the same patient. (c) A 7-year-old male patient (#117) with focal keratoderma and no nail involvement. (d) Hypertrophic nails that had appeared after local trauma in a 72-year-old female patient (#106). (e–g): skin biopsy taken from the affected area with a 4-mm punch. (e) Low-power magnification view of the entire biopsy stained for H&E. (f–g) The insets taken from (e) at higher magnification showing the hyperkeratosis area and the epithelium, respectively. Scale bar is 500 μm in panel e and 200 μm in panels f–g.

obtained applying theoretical methods implemented in several *in silico* sequence-based tools (reviewed in 11). Here, we have analysed p.Leu421Pro and results show that this change is as pathogenic as other disease-causing mutations found previously in *KRT16* (Table S1). For this analysis, four previously reported recurrent *KRT16* mutations were considered as ‘positive controls’. In addition, two other fictitious mutations affecting less conserved positions were also analysed as putative ‘negative (or non-disease causing) controls’, validating this method.

Mutations in residues homologous to K16 p.Leu421 have been also described in other keratins of types I and II (Table S2, data from www.interfil.org), including the same amino acid substitution. Most of the patients with these mutations showed typical or severe phenotypes (2,8,10,12–18), with the most extreme phenotype documented being an atypical Meesmann corneal dystrophy (MECD) due to a mutation in K12 p.Leu433Arg (19).

Conclusions

In summary, we report here a new mutation in *KRT16* (p.Leu421-Pro) in a large family. This mutation was present in heterozygous

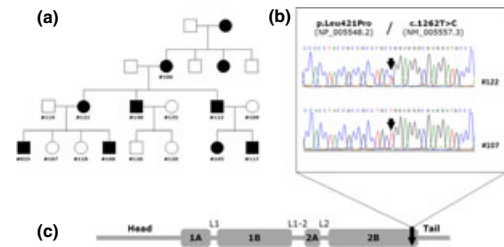


Figure 2. (a) Pedigree of the affected family, samples were from numbered individuals. (b) Sequence analysis of the exon 7 from an affected individual #122 compared with individual #107 from the same family without the phenotypic characteristics of the disease. (c) Structure of the K16 protein and position of the mutation. Keratins share a common protein structure consisting of a central alpha-helical rod domain of 310 residues divided into 1A, 1B, 2A and 2B domains connected by non-helical linker regions (L1, L1-2 and L2). The rod domain is flanked by short regions of sequence homology (H1 and H2), followed by the variable domains non-helical head (V1) and tail (V2). At either end of the rod domain are the helix boundary motifs (the helix initiation motif and the helix termination motif) that mediate end-to-end interactions during filament assembly.

state in all affected individuals examined. Bioinformatic analyses and the presence of homologous mutations in other keratins suggest that this change has a functional role in the disease. This mutation is located in HTM, the most conserved region between different keratins but infrequently mutated in this gene. Although homologous mutations in other keratins could promote severe phenotypes, this and the other case (a deletion) described to date affecting K16 HTM are associated with milder phenotypes in which affected tissue is the one which undergoes the highest daily trauma. This fact could be relevant to understand the functional role of this domain and could be also important for the diagnosis and the development of new treatments for patients with these mutations (20).

Acknowledgements

This study was supported by PIUNA Programme of the University of Navarra. We thank Dr Jose Luis Lanciego for his work with the cytological images and Dra Laura Kusinski for helpful comments on the manuscript.

Author contributions

FP, CH and JLV performed the research. AA contributed samples and clinical data. FP, LA and JLV analysed the data. FP and JLV designed the study and wrote the paper.

Conflict of interests

The authors have no conflict of interest to declare.

References

- McLean W H I, Hansen C D, Eliason M *et al.* *J Invest Dermatol* 2011; **131**: 1015–1017.
- Smith F J, Liao H, Cassidy A J *et al.* *J Invest Dermatol Symp Proc* 2005; **10**: 21–30.
- Wilson N J, Messenger A G, Leachman S A *et al.* *J Invest Dermatol* 2010; **130**: 425–429.
- McLean W H I, Rugg E L, Lunny D P *et al.* *Nat Genet* 1995; **9**: 273–278.
- Shamsher M K, Navsaria H A, Stevens H P *et al.* *Hum Mol Genet* 1995; **4**: 1875–1881.
- Leachman S A, Kaspar R L, Fleckman P *et al.* *J Invest Dermatol Symp Proc* 2005; **10**: 3–17.
- Smith F J, Fisher M P, Healy E *et al.* *Exp Dermatol* 2000; **9**: 170–177.
- Liao H, Sayers J M, Wilson N J *et al.* *J Dermatol Sci* 2007; **48**: 199–205.
- Fu T, Leachman S A, Wilson N J *et al.* *J Invest Dermatol* 2011; **131**: 1025–1028.
- Wilson N J, Leachman S A, Hansen C D *et al.* *J Invest Dermatol* 2011; **131**: 1018–1024.
- Thusberg J, Vihinen M. *Hum Mutat* 2009; **30**: 703–714.
- Virtanen M, Smith S K, Gedde-Dahl T Jr *et al.* *J Invest Dermatol* 2003; **121**: 1013–1020.
- Hut P H, v d Vlies P, Jonkman M F *et al.* *J Invest Dermatol* 2000; **114**: 616–619.
- Schuilenga-Hut P H, Vlies P, Jonkman M F *et al.* *Hum Mutat* 2003; **21**: 447.
- Lee D Y, Ahn K S, Lee C H *et al.* *J Invest Dermatol* 2002; **119**: 976–977.
- Arin M J, Oji V, Emmert S *et al.* *Br J Dermatol* 2011; **164**: 442–447.
- Osawa R, Akiyama M, Izumi K *et al.* *J Am Acad Dermatol* 2011; **64**: 991–993.
- Terrononi A, Smith F J, Didona B *et al.* *J Invest Dermatol* 2001; **117**: 1391–1396.
- Seto T, Fujiki K, Kishishita H *et al.* *Jpn J Ophthalmol* 2008; **52**: 224–226.
- Chamcheu J C, Wood G S, Siddiqui I A *et al.* *Exp Dermatol* 2012; **21**: 481–489.

Supporting Information

Additional Supporting Information may be found in the online version of this article:

Table S1. Results from the bioinformatic analyses of several sequence changes.

Table S2. Mutations reported to date in other type I and II keratins affecting *KRT16* p.Leu421 homologous residue.

Data S1. Bioinformatic analysis of p.Leu421Pro.

Figure S1. Comparative analysis of amino acid sequence of K16 2B domain.